

Surgeon at work

# Combined endoscopic-laparoscopic T-tube insertion for the treatment of staple-line leak after sleeve gastrectomy: a simple and effective therapeutic option

Marco Barreca, M.D.<sup>\*</sup>, Carlo Nagliati, M.D., Vigyan K. Jain, M.B.B.S.,  
Douglas E. Whitelaw, M.B.Ch.B.

*Department of Surgery, Luton & Dunstable University Hospital, NHS FT*

Received December 5, 2014; accepted December 15, 2014

## Abstract

**Background:** Management of staple-line leak after laparoscopic sleeve gastrectomy (LSG) remains controversial and matter of debate. Transforming a leak into a controlled fistula by insertion of a T-tube is a viable option. To minimize surgical dissection, and to facilitate identification of the leak site and insertion of the T-tube, we have developed a combined endoscopic-laparoscopic T-tube (ELT-t) insertion technique.

**Methods:** Between February 2011 and June 2014, 7 patients presented with staple-line leak and were treated with ELT-t insertion. After laparoscopic dissection of the abscess cavity, a guidewire is passed endoscopically through the leak; a polypectomy snare is anchored to the guidewire and retrieved through the patient mouth. The long arm of a T-tube is eventually secured to the snare and pulled down through the leak.

**Results:** All patients were started on oral feeding with the T-tube in place. Serial water-soluble contrast swallows were performed to check for healing, and the T-tube was clamped as soon as no extravasation of contrast was demonstrated. The tube was removed either during the index admission or in the outpatient clinic. The residual fistula closed successfully after T-tube removal in all but one case with a “spiral-shaped” sleeve and functional distal obstruction. This patient was treated with stent. Patients were discharged home after a mean postoperative hospital stay of 53.3 days (range: 15–87 days).

**Conclusion:** In our experience, ELT-t is a valid alternative for the treatment of staple-line leak after LSG. It allows minimizing surgical dissection, and appears to be safe and effective. (*Surg Obes Relat Dis* 2015;11:479–482.) © 2015 American Society for Metabolic and Bariatric Surgery. All rights reserved.

## Keywords:

Sleeve gastrectomy; Staple-line leak; Treatment options; T-tube; Laparoscopy; Endoscopy

Laparoscopic sleeve gastrectomy (LSG) has gained popularity as stand-alone procedure for the treatment of morbid obesity [1], due to its apparent technical simplicity, and its excellent results compared with Roux-en-Y gastric bypass.

LSG carries specific postoperative complications such as staple-line leak, bleeding, and stenosis [2]. Staple-line leaks occur in up to 7% of patients, mainly at the gastroesophageal junction (GOJ), and carry a mortality of .11% [3,4].

Our aim is to present a technique of endoscopic-laparoscopic T-tube (ELT-t) insertion for treatment of staple-line leak after LSG, and the related outcomes.

Between February 2011 and June 2014, 7 patients were treated at our institution for acute-early (1–30 days

<sup>\*</sup>Correspondence: Dr. Marco Barreca, Luton & Dunstable University Hospital, NHS FT, Department of Surgery, Lewsey Road, Luton LU4 0DZ, United Kingdom. Tel.: +44 015 824 97104; fax: +44 015 824 97104.  
E-mail: [marco.barreca@ldh.nhs.uk](mailto:marco.barreca@ldh.nhs.uk)

postoperatively) leak. Abdominal pain, tachycardia, and signs of sepsis were the most common clinical findings. All patients underwent oral/intravenous contrast CT-scan, which confirmed extravasation of contrast and/or an intra-abdominal collection. Patients were admitted a mean of 11.2 days after the original operation (range: 6–30 days). After initial resuscitation and antibiotic therapy, all patients underwent an exploratory laparoscopy and were treated with washout, drainage and ELT-t insertion.

The procedure begins with identification and minimal dissection of the intraabdominal collection, followed by extensive washout of the abdominal cavity. In preparation for the intraoperative endoscopy, an enteric clamp occludes the duodenum, to avoid dilation of the small bowel, which limits subsequent laparoscopic view. The gastroscopy allows endoluminal identification of the defect, and examination of the entire sleeve. A hydro-pneumatic test is performed inflating air with the endoscope and irrigating the leak site. Air-bubbles confirm the presence of a leak, and allow keeping the surgical dissection to the minimum. A guidewire (red in the figure) then is passed through the working channel of the endoscope across the leak into the peritoneal cavity (Fig. 1A). The guidewire is pulled through one port outside the abdomen; a polypectomy snare (blue) is secured to it (Fig. 1B), and pulled, through the defect and the esophagus (Fig. 2A), out of the patient's mouth. The long-arm of a 12 or 24Fr T-tube (orange) is anchored to the snare, pulled down (Fig. 2B), passed through the leak and brought outside the abdomen. Two drains are positioned: one around the leak, one in the splenic space. A feeding jejunostomy can be performed for postoperative feeding.

We monitored all patients in the intensive care unit for at least 24 hours, and total parenteral nutrition or enteral feeding was started after the first postoperative day. To check for leak healing, we performed serial water-soluble contrast swallows as soon as the signs of sepsis resolved and the drain output reduced significantly. We started oral feeding with the T-tube still in place after a mean of 42.5 days (range: 6–75), and discharged all patients home after a mean postoperative hospital stay of 53.3 days (range: 15–87). Based on imaging results (i.e., no residual abscess cavity), the T-tube was initially clamped, and subsequently removed after a mean of 62 days (range: 20–105). The T-tube was removed in the outpatient clinic after discharge, except for the first patient for whom removal occurred during the index hospitalization. The fistula closed successfully within ten days from T-tube removal in all but one patient, who had a “spiral-shaped” sleeve. In this patient the fistula failed to heal 6 months after T-tube removal, and was eventually treated successfully with repeated stenting. At 6 months no sequelae or mortality were observed.

Our experience shows that transforming a contained leak into a controlled fistula by T-tube insertion is a valid treatment option. To identify the leak with minimal surgical dissection, and to facilitate the T-tube insertion, we propose a combined endoscopic-laparoscopic T-tube insertion technique, which appears safe, effective and easily reproducible. To our knowledge, this is the first description of the management of staple-line leak post LSG by such technique.

Staple-line leak is the most dreaded complication after LSG, due to the associated risk of death and major

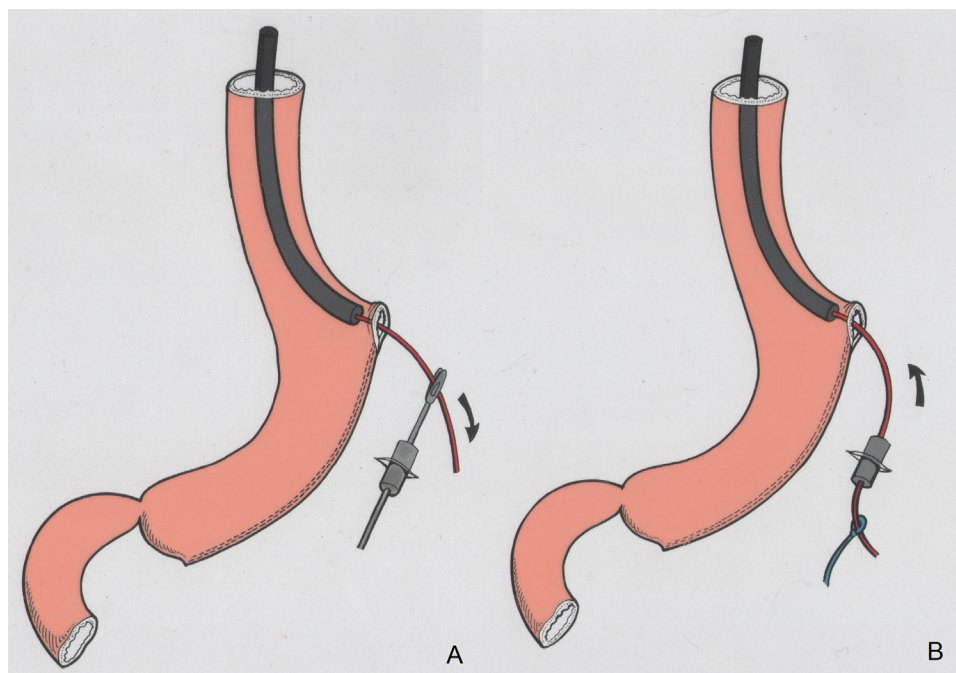


Fig. 1. (A) A guidewire is passed using the working channel of an endoscope across the leak and is retrieved outside the abdominal wall, (B) A polypectomy snare is secured to the guidewire.

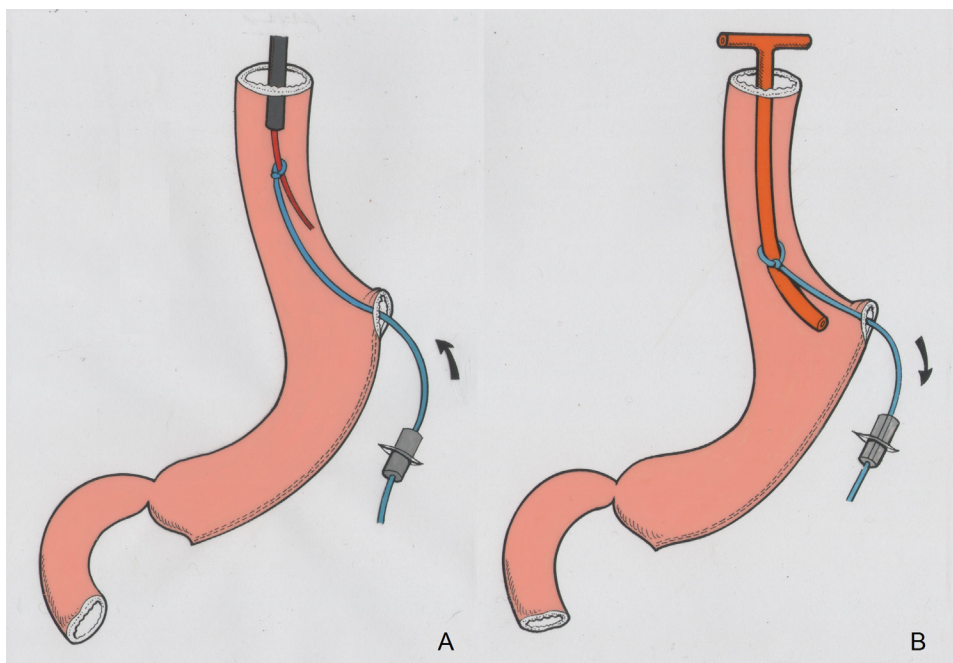


Fig. 2. (A) The endoscope, guidewire and polypectomy snare are withdrawn back and removed from the patient mouth, (B) The long-arm of a T-tube is secured to the polypectomy snare and is pulled down the esophagus and across the leak.

morbidity. Its treatment is challenging because of the “high-pressure” existing within the gastric tube [5].

LSG leak management remains controversial and may depend on the experience of the surgeon and the patient’s clinical conditions. Several options have been described with variable results, including percutaneous drainage [6], intraluminal therapies (e.g., endoscopic stents [7], clips [8]), and surgical revision (i.e., primary closure, Roux-en-Y gastrojejunostomy or esophago-jejunostomy, or jejunal patch over the leak) [2].

Treatment of early staple-line leak with stents has recently gained popularity [2–4], but its efficacy and safety remain controversial. Uncoated or partially covered stents can be difficult to remove, and may require further endoscopic treatment [9] or surgical removal, and late total gastrectomies have been reported [10]. Treatment failure and premature removal have been reported in up to 55–85% of patients [11,12]. Several attempts to position a stent in the same patient are not uncommon, and severe complications (i.e., severe pain, reflux, vomiting, hematemesis and obstruction from kinking) occur in up to 60% of patients [11]. Stent migration requiring endoscopic removal or replacement [10], acute gastrointestinal bleeding and fatal aorto-esophageal fistula have also been reported [13,14].

The proposed ELT-t appears to be an alternative safe and effective approach to treat LSG leaks. It significantly minimizes the need for surgical dissection around the leak, reducing the risk of adjacent organ injuries.

Successful treatment of proximal staple-line leaks with laparoscopic transorificial intubation of the leak with a T-tube has been reported in 2 [15] and 3 patients [12]

respectively with a defect large enough to be visualized laparoscopically. Intraoperative identification of the leak is not always easy, and is a limiting factor for T-tube insertion [15]. Our technique overcomes this problem thanks to the endoscopic visualization of the defect, and can thus be employed on a wider scale. Furthermore, by endoluminally localizing the defect, our ELT-t technique has the advantage of minimizing the laparoscopic dissection, eliminating the risk of widening the leak and of minimizing the risk of damaging the surrounding structures (e.g., diaphragm, spleen), and allows the correct positioning of the T-tube in all circumstances.

We do not advocate the use of ELT-t when there is radiological or endoscopic evidence of a stricture or a “spiral-shaped” appearance of the sleeve with concomitant distal functional obstruction, as the remaining fistula is very unlikely to subsequently close. In these instances, the drainage of the abscess and the insertion of a T-tube still represent an *interim* solution, and can be used to stabilize the patient before final treatment with a stent.

In conclusion, our experience has shown that treating LSG leaks with drainage, washout, ELT-t insertion and abdominal drains reduces intraabdominal contamination, allows drainage of the collection and creates a controlled fistula, which eventually will close spontaneously.

## Disclosures

*The authors have no commercial associations that might be a conflict of interest in relation to this article.*

## References

- [1] Rosenthal RJ, Diaz AA, Arvidsson D, et al. International Sleeve Gastrectomy Expert Panel Consensus Statement: best practice guidelines based on experience of >12,000 cases. *Surg Obes Relat Dis* 2012;8:8–19.
- [2] Brethauer S. Sleeve Gastrectomy. *Surg Clin N Am* 2011;91:1265–79.
- [3] Parikh M, Issa R, McCrillis A, et al. Surgical Strategies That May Decrease Leak After Laparoscopic Sleeve Gastrectomy. *Ann Surg* 2013;257:231–7.
- [4] Aurora AR, Khaitan L, Saber AA, et al. Sleeve gastrectomy and the risk of leak: a systematic analysis of 4,888 patients. *Surg Endosc* 2012;26:1509–15.
- [5] Yehoshua RT, Eidelman LA, Stein M, et al. Laparoscopic sleeve gastrectomy – volume and pressure assessment. *Obes Surg* 2008;18:1083–8.
- [6] Corona M, Zini C, Allegritti M, et al. Minimally invasive treatment of gastric leak after sleeve gastrectomy. *Radiol Med* 2013;118:962–70.
- [7] Eisendrath P, Cremer M, Himpens J, et al. Endotherapy including temporary stenting of fistulas of the upper gastrointestinal tract after laparoscopic bariatric surgery. *Endoscopy* 2007;39:625–30.
- [8] Aly A, Lim HK. The use of over the scope clip (OTSC) device for sleeve gastrectomy leak. *J Gastrointest Surg* 2013;17:606–8.
- [9] Jen S, Simillis C, Efthimou E. A very challenging leak from a sleeve gastrectomy. *Surg Obes Relat Dis* 2013;9:e56–9.
- [10] Simon F, Siciliano I, Gillet A, et al. Gastric leak after laparoscopic sleeve gastrectomy: early covered self-expandable stent reduces healing time. *Obes Surg* 2013;23:687–92.
- [11] Tan JT, Kariyawasam S, Wijeratne T, et al. Diagnosis and management of gastric leaks after laparoscopic sleeve gastrectomy for morbid obesity. *Obes Surg* 2010;20:403–9.
- [12] Moszkowicz D, Arienzo R, Khettab I, et al. Sleeve gastrectomy severe complications: is it always a reasonable surgical option? *Obes Surg* 2013;23:676–86.
- [13] Rebibo L, Fuks D, Blot C, et al. Gastrointestinal bleeding complication of gastric fistula after sleeve gastrectomy: consider pseudoaneurysms. *Surg Endosc* 2013;27:2849–55.
- [14] Almadi MA, Bamhriz F, Aljebreen AM. Fatal aortoesophageal fistula bleeding after stenting for a leak post sleeve gastrectomy. *World J Gastrointest Surg* 2013;5:337–40.
- [15] El Hassan E, Mohamed A, Ibrahim M, et al. Single-stage operative management of laparoscopic sleeve gastrectomy leaks without endoscopic stent placement. *Obes Surg* 2013;23:722–6.