

## Original article

Bile reflux of the remnant stomach following Roux-en-Y gastric bypass:  
an etiology of chronic abdominal pain treated with remnant gastrectomyErika La Vella, D.O.<sup>a,b,\*</sup>, Zach Hovorka, D.O.<sup>a,b</sup>, Donald E. Yarbrough, M.D.<sup>a</sup>,  
Elizabeth McQuitty, M.D.<sup>a,c</sup><sup>a</sup>Samaritan Weight Management and Metabolic Surgery Institute, Corvallis, Oregon<sup>b</sup>Department of Surgery, Western University College of Osteopathic Medicine Pacific Northwest, Corvallis, Oregon<sup>c</sup>Department of Pathology, Good Samaritan Regional Medical Center, Corvallis, Oregon

Received January 19, 2017; accepted April 6, 2017

## Abstract

**Background:** Bile reflux gastritis of the remnant stomach following Roux-en-Y gastric bypass (RYGB) causing chronic abdominal pain has not been reported. We report a series of symptomatic patients with remnant gastritis treated effectively with remnant gastrectomy (RG).**Objective:** The objective was to report our experience with bile reflux remnant gastritis after RYGB and our outcomes following RG.**Setting:** Community teaching hospital.**Methods:** All patients undergoing RG were retrospectively reviewed for presenting symptoms, diagnostic workup, pathology, complications, and symptom resolution.**Results:** Nineteen patients underwent RG for bile reflux gastritis at a mean of 4.4 years (52.3 mo, range 8.5–124 mo) after RYGB. All patients were female and presented with pain, primarily epigastric (18/19; 95%), and described as burning (11/19; 58%), with 10 (53%) reporting nausea. Endoscopy was performed preoperatively on all patients with successful remnant inspection in 13 (68%), using push endoscopy (n = 10) or operative assist (n = 3), with 12 (of 13; 92%) biopsy-positive for reactive gastropathy. Seventeen (90%) completed a hepatobiliary scintigraphy scan with 100% positivity demonstrating bile reflux across the pylorus. Surgical approach was laparoscopic or robotic in 18 (95%) with a hospital length of stay of 2.7 days (range 0–12 d), with no major complications or readmissions. Pathology of the remnant confirmed reactive gastropathy in 90% (n = 17). Ninety percent of patients (n = 17) reported sustained symptom resolution, and 11% of patients (n = 2) remained symptomatic at last follow-up. We followed all patients for a mean of 6.6 years (1–194 mo).**Conclusion:** Bile reflux gastritis of the remnant stomach is a new consideration for chronic abdominal pain months to years following RYGB. Hepatobiliary scintigraphy imaging and endoscopic biopsy are highly suggestive. RG is safe and effective treatment. (*Surg Obes Relat Dis* 2017;13:1278–1283.) © 2017 American Society for Metabolic and Bariatric Surgery. All rights reserved.

## Keywords:

Roux-en-y gastric bypass; Complications; Bile reflux; Remnant gastritis; HIDA; Revision

Roux-en-Y gastric bypass (RYGB) is one of the most common and effective metabolic surgery procedures [1].

However, there are several reported long-term complications [2]. Chronic abdominal pain after RYGB is an especially difficult entity to diagnose and treat. Previously described late presentations of abdominal pain after RYGB are caused by internal hernia, anastomotic structure, bowel obstruction, marginal ulcer, cholecystitis, and intussusceptions, but causes of abdominal pain not explained by these

\*Correspondence: Erika La Vella, D.O., Samaritan Weight Management and Metabolic Surgery Institute, 3517 NW Samaritan Dr, Suite 100, Corvallis, OR 97330.

E-mail: lavellaerika@gmail.com

mechanisms are largely unknown [3]. One potentially underreported etiology of chronic abdominal pain after RYGB appears to be bile reflux remnant gastritis.

Pathology of the remnant stomach can be difficult to diagnose because of the altered anatomy making endoscopic evaluation a challenge. Previous studies have demonstrated the ability to use endoscopy, especially double-balloon enteroscopy, to access the remnant stomach [4,5]. Others have demonstrated the use of hepatobiliary scintigraphy (HIDA) to document the flow pattern of bile in the workup of duodenogastric reflux seen in postcholecystectomy syndromes and gastroparesis of the bypassed stomach [6–9]. The presence of bile is known to injure the gastric mucosal barrier leading to gastritis and intestinal metaplasia in asymptomatic RYGB patients [9–11].

To date, there is no published literature of bile reflux gastritis of the remnant stomach as a cause of chronic pain, nor are there reports of such etiology being treated with remnant gastrectomy (RG). We report a series of symptomatic patients months to years after RYGB with chronic abdominal pain in the setting of bile reflux remnant gastritis treated effectively with RG. We demonstrate that RG is a safe and effective treatment for bile reflux remnant gastritis.

## Methods

After obtaining institutional review board approval, all patients who underwent RG after a previous RYGB between March 2000 and March 2016 for chronic abdominal pain were identified. The data collected included age, gender, symptoms, surgery, diagnostics, time from RYGB to RG, and endoscopic findings. HIDA was considered positive if contrast refluxed into the remnant stomach. After excluding other diagnoses, bile reflux gastritis was assumed with any one of the following: 1) HIDA with bile flow into the remnant stomach, 2) endoscopic findings of bile staining and erythema of the remnant stomach grossly, or 3) endoscopic biopsies demonstrating reactive gastropathy (Fig. 1). Additional data included minor and major complications, symptom resolution, operative pathology, and follow-up duration. Chart notes and structured phone interviews were utilized to determine outcome of surgery.

### Histopathologic evaluation

Hematoxylin and eosin stained slides were collected from the archives of the pathology department and reviewed

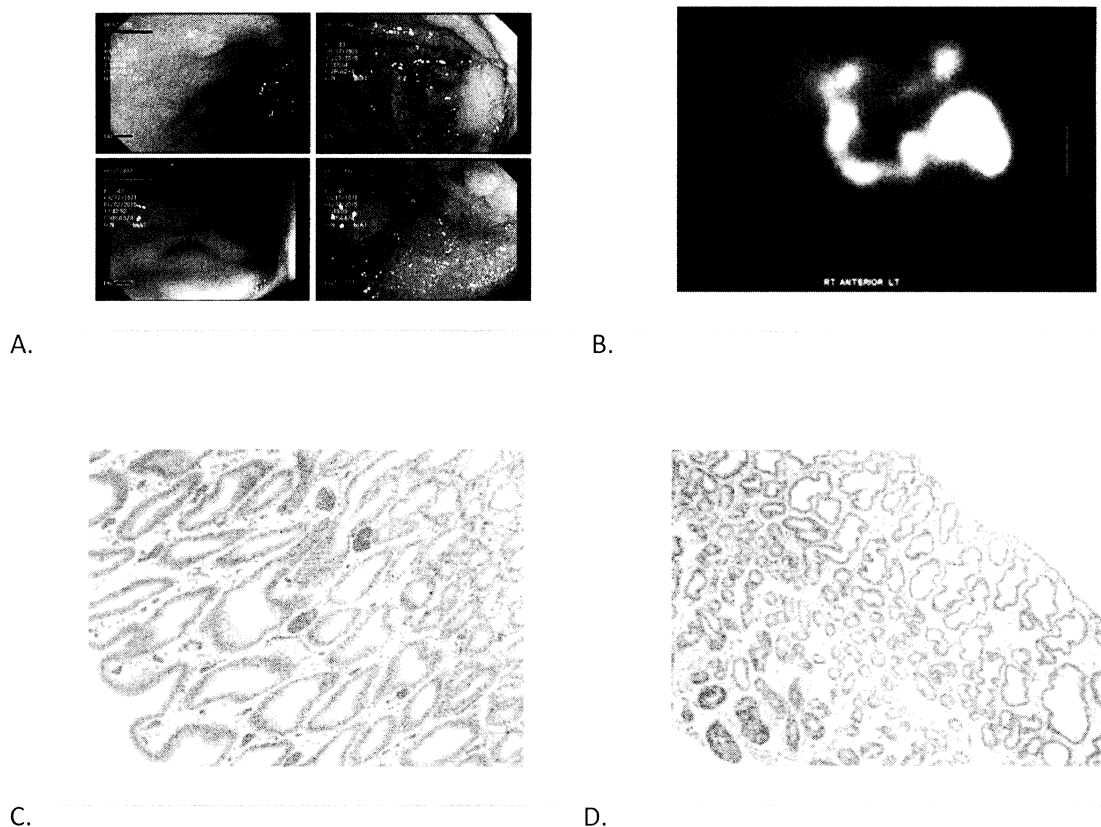


Fig. 1. (A) Endoscopic findings of the remnant stomach in a 43 year old female 12 months after RYGB. Note the erythema and presence of bile near the antrum. (B) HIDA scan demonstrating bile flow pattern into the remnant stomach in the same patient. (C,D) Hematoxylin and eosin stained slides demonstrating reactive gastropathy.

by a single pathologist (E.M.). Where available, slides representing the preoperative gastric remnant biopsy and the corresponding completion gastrectomy specimen were reviewed.

Criteria for a diagnosis of reactive gastropathy included marked foveolar hyperplasia, mucin depletion, and lamina propria smooth muscle hyperplasia in a background of sparse chronic inflammation, vascular congestion, and edema. Cases with multiple unambiguous features of reactive gastropathy were scored as such. Cases with some, but not all features, and those with more subtle findings were designated as having “features of reactive gastropathy.” Cases without features of reactive gastropathy were scored as “negative for reactive gastropathy.”

### Surgical technique

RG was performed via laparotomy in one case and with minimally invasive techniques in 18 (95%; 12 laparoscopic, 6 robotic). After general anesthesia and trocar placement (5 or 6), the abdomen was insufflated to 15 mmHg. The abdomen and internal hernia spaces were inspected. Any adhesions between the liver and the remnant stomach were taken down and liver retracted. The greater and lesser curves were devascularized from pylorus to fundus until the entire stomach was free, taking care to preserve the roux limb and mesentery. The dissection was continued just beyond the pylorus on to the duodenum and the duodenum divided with an endomechanical stapler. Omentum was secured over the duodenal staple line with 2-0 Vicryl in most cases. The specimen was removed with an Endocatch bag via a 12-mm trocar in the right upper quadrant. All trocar sites were sutured closed and injected with local anesthesia.

### Results

Nineteen patients underwent RG for diagnosis of bile reflux gastritis at a mean of 4.4 years following RYGB (52.3 mo, range 8.5–124 mo). Three of 19 patients had initial RYGB at an outside institution. We have performed a total of 572 RYGB at our institution, giving bile reflux gastritis a prevalence of 2.7%. All patients were female. Presenting symptoms included pain in the epigastrium (94.7%), left upper quadrant (10.5%), right upper quadrant (10.5%), or left shoulder (5.3%). Pain was regarded as burning (57.9%), sharp (36.8%), or stabbing (5.3%). Five of 19 patients (26%) described esophageal reflux symptoms. Nausea and vomiting were common in 10 (53%) and 8 patients (42%), respectively. All patients were on a proton pump inhibitor before RG (Table 1).

All patients underwent workup to rule out other pathologies such as internal hernia, superior mesenteric artery syndrome, marginal ulcers, strictures, and cholecystitis. Abdominal computed tomography or magnetic resonance imaging were performed in 14 patients (73.7%), upper

Table 1

Characteristics of 19 patients undergoing RG after RYGB for bile reflux remnant gastritis

Characteristics	N
Age, yr, median (range)	41 (31–68)
Gender, %	
Female	100
BMI before RYGB, kg/m <sup>2</sup>	51.7
BMI after RG, kg/m <sup>2</sup>	28.5
Mean time to RG after RYGB, mo, median (range)	52.3 (8.5–124)
Symptoms, n (%)	
Abdominal pain	19 (100)
Nausea	10 (52)
Vomiting	8 (42.1)
Prior cholecystectomy, n (%)	17 (89.5)
Diagnostic methods, n (%)	
CT/MRI	14 (73.7)
HIDA	17 (89.5)
Upper GI	5 (26.3)
Ultrasound	3 (15.8)
Endoscopy	13 (68.4)
Follow-up after RG, mo, median (range)	79 (1–194)

BMI = body mass index; RYGB = Roux-en-Y gastric bypass; RG = remnant gastrectomy; CT = computed tomography; MRI = magnetic resonance imaging; HIDA = hepatobiliary scintigraphy scan; GI = gastrointestinal.

gastrointestinal series in 5 patients (31.6%), and ultrasound in 3 patients (15.8%). On computed tomography scan, one patient had a dilated remnant stomach > 10 cm in diameter, whereas the remainder had remnant stomach measurements between 2 and 4 cm in diameter and appeared decompressed. Gas within the remnant stomach was also present in a select few. Five patients (26%) were previously treated for internal hernia, strictures, intussusception, or ulcers and found to have negative workup for these issues at time of RG. Three patients (15.8%) had cholecystectomy before RYGB, and 17 (89.4%) had cholecystectomy before RG with no evidence of acute biliary pathology before RG.

All patients underwent endoscopy before RG, and endoscopic evaluation of the remnant stomach was successful in 68% (n = 13) through retrograde access with a pediatric colonoscope (n = 10) or with operative assistance (n = 3). Our institution does not perform double-balloon endoscopy. Endoscopic biopsy correlated with final operative pathology in 92% specimens (n = 12). Seventeen of 19 patients (90%) had “reactive” or “features of” gastropathy of the remnant stomach on final pathology. For the purposes of our study, “features of gastropathy” was considered positive for bile reflux gastritis. All patients had HIDA exam. A positive HIDA correlated with reactive gastropathy in 79% (n = 15), giving a positive predictive value of 88% and sensitivity of 88% (Table 2).

Eighteen of 19 patients underwent laparoscopic or robotic assisted RG. Eighteen patients (95%) reported symptom improvement within 2 weeks following RG, whereas 16 (84%) reported complete symptom resolution at a mean follow-up of 6.5 years (1–194 mo).

Table 2

Comparison of endoscopic results, cholescintigraphy, operative pathology, symptom resolution, and follow-up

Patient #	Endoscopic biopsy	HIDA	Operative pathology	Symptom resolution	Length of follow-up (mo)
1	Negative	Positive	Negative	Yes	25.6
2	Positive	Positive	Positive	Yes	23.0
3	Positive	Negative	Positive	No (chronic pain)	92.7
4	N/A	Positive	Positive	Yes	23.2
5	N/A	Positive	Negative	No (nausea)	109.1
6	N/A	Positive	Positive	Yes	113.8
7	N/A	Positive	Positive	Yes	26.1
8	Positive	Positive	Positive	Yes	108.0
9	Positive	Positive	Positive	Yes	88.4
10	Positive	Positive	Positive	Yes	144.2
11	Positive	Negative	Positive	Yes	88.5
12	Positive	Positive	Positive	Yes	66.8
13	Positive	Positive	Positive	Yes	24.5
14	N/A	Positive	Positive	Yes	194.2
15	Positive	Positive	Positive	No	102.5
16	Positive	Positive	Positive	Yes	104.0
17	Positive	Positive	Positive	Yes	92.3
18	Positive	Positive	Positive	Yes	1.5
19	N/A	Positive	Positive	Yes	1.0

HIDA = hepatobiliary scintigraphy scan; N/A = not applicable.

Gross endoscopy positive indicates bile staining and erythema. Cholescintigraphy HIDA positive indicates reflux into gastric remnant. Operative pathology positive indicates gastropathy.

### Complications

There was one early minor complication, a superficial wound infection in a female aged 43 who underwent open laparotomy for RG 11 months following RYGB. She required intravenous antibiotics and a peripherally inserted central catheter line at discharge. She was discharged on postoperative day 4.

There was one major late complication, a perforated ulcer at the gastrojejunostomy anastomosis 6 weeks after uneventful RG in a 38-year-old female 6 years following RYGB. An esophagogastroduodenoscopy before RG did not demonstrate a marginal ulcer at the gastrojejunostomy. At readmission, she reported alcohol abuse and nonsteroidal anti-inflammatory drug (NSAID) usage. She underwent emergent laparotomy for repair and was lost to follow-up following this event.

### Follow-up

Patient records were retrospectively reviewed followed by a structured telephone survey conducted in March of 2016. Fourteen patients (74%) were reached by telephone survey with an average follow-up of 6.5 years. Seventeen patients (90%) had follow-up greater than 23 months, and 12 patients (63%) had follow-up greater than 5 years. Of those reached by survey, 2 of 14 (14%) reported occasional nausea and postprandial pain. The remaining 12 reported complete symptom resolution (86%). Two patients (14%) reported need for repeat endoscopy for the monitoring of ulcers and strictures. Four patients (28%) remain on proton-pump-inhibitor, and 1 patient (7%) reported being on opiates for chronic pain.

### Discussion

Abdominal pain caused by bile reflux remnant gastritis has not been described in the literature until recently [12]. The etiology is not well understood; however, several theories exist. Sundbom et al. estimated that the occurrence of bile reflux into the remnant is 36% using HIDA in asymptomatic patients [8]. They hypothesized that gastritis occurs secondary to the absence of saliva and food washing bile from the stomach, which is additionally compounded by alterations in expression of nervous and endocrine signaling damaging the mucosal barrier and thus is the precursor to injury [8].

Ahmad et al. studied the effect of cholecystectomy on duodenogastric reflux in individuals without RYGB and found that, postcholecystectomy, the rates of reflux double from 23.3% preoperatively to 46.6% postoperatively [7]. Bile refluxes more freely into the stomach because of pylorus relaxation after cholecystectomy and the loss of gallbladder reservoir function [8]. In our study, 88% of patients ( $n = 17$ ) had prior cholecystectomy which may have contributed to the severity of their symptoms and bile reflux.

In addition to the deleterious effects of bile on the gastric mucosa, gastroparesis has been hypothesized as a contributing factor. Tarakji et al. have presented a case study of a woman with abdominal pain following RYGB [6]. HIDA demonstrated bile reflux into the remnant and with significant isotope activity in the remnant at 2 hours [6]. The patient's symptoms did not improve with prokinetic agents, and she was trialed for 1 month with gastrostomy tube, which alleviated her symptoms [6]. In our study, we did not

test for gastroparesis. Our HIDA studies were carried out through 60 minutes, but in review, most had isotope activity at 60 minutes. The incidence of gastroparesis in our patients before and after RYGB is unknown and is perhaps a contributing factor. Future study is needed to determine if there is a relationship between gastroparesis and bile reflux.

We treated bile reflux remnant gastritis with RG and demonstrated that it is a safe operation with little morbidity in both the short and long term. Csendes et al. advocated for RG at the time of RYGB for different reasons, such as potential for cancer, gastric ulcers, gastritis, bleeding, and duodenal ulcers in the difficult-to-access remnant in patients with long life expectancies [3]. They also speculated that marginal ulceration is partially due to production of hydrochloric acid exacerbated by large gastric pouch and retained antrum [3]. Csendes et al. used a surgical technique similar to our series with division of the duodenum 1–2 cm distal to pylorus [3]. After gastrectomy, they reported no cases of anastomotic ulceration [3]. Postoperative complications were differentiated as those typical of RYGB and those specifically associated with gastrectomy with a total complication rate of 4.75% and reoperation rate of 2.25% [3]. Complications that attributed to the gastrectomy were bleeding (.25%), necrosis with abscess of greater omentum (.25%), and duodenal stump leakage (.25%) [3].

The safety of RG was additionally discussed by Cho et al., who performed laparoscopic RG (n = 15) for the treatment of gastrogastic fistula [12]. Their RG differed from our technique in that they left the antrum behind [12]. Indications for RG were intractable epigastric pain, upper GI bleeding, intolerance of soft diet, and weight regain [12]. As we report here, their RG complication rate was similarly low, including bleeding requiring exploration (n = 1), pneumonia and/or wound infection (n = 5), fever (n = 1), and food impaction (n = 1) [12].

One abstract report suggests that bile reflux remnant gastritis can be safely treated with bile-thinning medications. Schulman and Thompson [13] from Brigham and Women's Hospital in Boston have identified bile reflux remnant gastritis as a cause of chronic abdominal pain following RYGB. HIDA was used to document reflux into the remnant; however, the authors treated their patients with Ursodiol at 500 mg twice daily (BID) and escalated dosing to 1000 mg BID if necessary. They found 25 patients with HIDA suggestive of reflux; Ursodiol treatment was successful at 500 mg BID in 80% of patients and, with escalation to 1000 mg BID, increased to 88%.

The irreversibility of RG may be criticized, but no long-term data suggest that risks outweigh the benefits. Moon et al. [14] presented that indications for reversal typically are recurrent anastomotic ulcer, intractable nausea and emesis, hypocalcemia, and neuroglycopenia. In our experience, many patients do not want their bypass reversed for fear of weight regain and return of medical co-morbidities. Moon et al. showed that of the 8 patients studied following

reversal of RYGB, 5 did experience weight regain [14]. Future study is needed to establish patient satisfaction and the long-term sequelae of RG and reversal of RYGB.

### Limitations

Our series has several limitations. It is a case series in which selection bias and confirmation bias are likely evident. We were only able to demonstrate the sensitivity of HIDA scan but not specificity. Future prospective study is needed. Additionally, we have a limited sample size.

It should also be added that the alcohol and NSAIDs in and of themselves cause reactive gastropathy [15]. As in our patient with the perforated gastrojejunostomy marginal ulcer described above, alcohol and NSAIDs may have been confounders in the interpretation of her pathology.

### Conclusion

Bile reflux remnant gastritis is a cause of chronic pain occurring months to years after RYGB. HIDA scan is a sensitive measure for remnant pathology and is a readily available noninvasive test. HIDA and endoscopic biopsies are highly suggestive of bile reflux remnant gastritis. RG is safe and effective treatment for bile reflux remnant gastritis with long-term symptom improvement and resolution in most patients. Further study is needed to better understand the mechanisms of bile reflux.

We recommend HIDA scan and endoscopy in all patients with chronic abdominal pain following RYGB after other common causes have been excluded with an escalating level of treatment from noninvasive, such as a trial of prokinetic medications or Ursodiol, to surgical treatment of RG or reversal of gastric bypass.

### Disclosures

*The authors have no commercial associations that might be a conflict of interest in relation to this article.*

### References

- [1] Rubino F, Nathan DM, Eckel RH, et al. Delegates of the 2nd Diabetes Surgery Summit. Metabolic surgery in the treatment algorithm for type 2 diabetes: a joint statement by international diabetes organizations. *Diabetes care* 2016;39(6):861–77.
- [2] Swartz DE, Mobley E, Felix EL. Bile reflux after Roux-en-Y gastric bypass: an unrecognized cause of postoperative pain. *Surg Obes Relat Dis* 2009;5(1):27–30.
- [3] Csendes A, Burdiles P, Papapietro K, et al. Results of gastric bypass plus resection of the distal excluded gastric segment in patients with morbid obesity. *J Gastrointest Surg* 2005;9(1):121–31.
- [4] Kuga R, Safatle-Ribeiro AV, Faintuch J, et al. Endoscopic findings in the excluded stomach after Roux-en-Y gastric bypass surgery. *Arch Surg* 2007;142(10):942–6.
- [5] Safatle-Ribeiro AV, Kuga R, Iriya K, et al. What to expect in the excluded stomach mucosa after vertical banded Roux-en-Y Gastric bypass for morbid obesity. *J Gastrointest Surg* 2007;11(2):133–7.

- [6] Tarakji AM, Morales F, Rovito P. Hepatobiliary scintigraphy as a diagnostic modality for gastroparesis of the bypassed stomach after gastric bypass for morbid obesity. *Obes Surg* 2007;17(3):414–5.
- [7] Ahmad BN, Ahmad WN, Aalam WK, Ahmad SM, Hussain KS. Duodenogastric reflux, an important cause of post cholecystectomy symptoms. *JK Practitioner* 2003;10(3):188–90.
- [8] Sundbom M, Hedenström H, Gustavsson S. Duodenogastric bile reflux after gastric bypass: a cholescintigraphic study. *Dig Dis Sci* 2002;47(8):1891–6.
- [9] Kennedy NS, Campbell FC, Cullen PT, Sutton DG, Millar BW, Cuschieri A. Gallbladder function and fasting enterogastric bile reflux. *Nucl Med Commun* 1989;10(3):193–8.
- [10] Srivastava A, Lauwers GY. Pathology of non-infective gastritis. *Histopathology* 2007;50(1):15–29.
- [11] Leuratti L, Di Simone MP, Cariani S. Unexpected changes in the gastric remnant in asymptomatic patients after Roux-en-Y gastric bypass on vertical banded gastroplasty. *Obes Surg* 2013;23(1):131–9.
- [12] Cho M, Kaidar-Person O, Szomstein S, Rosenthal RJ. Laparoscopic remnant gastrectomy: a novel approach to gastrogastic fistula after Roux-en-Y gastric bypass for morbid obesity. *J Am Coll Surg* 2007;204(4):617–24.
- [13] Schulman, Allison, Thompson Christopher C. Su1252 Utility of Bile Acid Scintigraphy in the Diagnosis of Remnant Gastritis in Patients With Roux-en-Y Gastric Bypass. *Gastrointest Endosc* 2016;83(5):AB327–AB328.
- [14] Moon RC, Frommelt A, Teixeira AF, Jawad MA. Indications and outcomes of reversal of Roux-en-Y gastric bypass. *Surg Obes Relat Dis* 2015;11(4):821–6.
- [15] Genta RM. Differential diagnosis of reactive gastropathy. *Semin Diagn Pathol* 2005;22(4):273–83.

## Original article

Cost of bariatric surgery and factors associated with increased cost:  
an analysis of national inpatient sample

Zhamak Khorgami, M.D.<sup>a,\*</sup>, Ali Aminian, M.D.<sup>b</sup>, Saeed Shoar, M.D.<sup>c</sup>, Amin Andalib, M.D.<sup>d</sup>,  
Alan A. Saber, M.D.<sup>c</sup>, Philip R. Schauer, M.D.<sup>b</sup>, Stacy A. Brethauer, M.D.<sup>b</sup>,  
Guido M. Sclabas, M.D.<sup>a</sup>

<sup>a</sup>Department of Surgery, University of Oklahoma, College of Medicine, Tulsa, Oklahoma

<sup>b</sup>Bariatric and Metabolic Institute, Department of General Surgery, Cleveland Clinic, Cleveland, Ohio

<sup>c</sup>Bariatric and Metabolic Institute, Department of Surgery, The Brooklyn Hospital Center, Icahn School of Medicine at Mount Sinai, Brooklyn, New York

<sup>d</sup>Center for Bariatric Surgery, Department of Surgery, McGill University, Montreal, Canada

Received December 11, 2016; accepted April 6, 2017

**Abstract**

**Background:** In the current healthcare environment, bariatric surgery centers need to be cost-effective while maintaining quality.

**Objective:** The aim of this study was to evaluate national cost of bariatric surgery to identify the factors associated with a higher cost.

**Setting:** A retrospective analysis of 2012–2013 Healthcare Cost and Utilization Project - Nationwide Inpatient Sample (HCUP-NIS).

**Method:** We included all patients with a diagnosis of morbid obesity (ICD9 278.01) and a Diagnosis Related Group code related to procedures for obesity, who underwent Roux-en-Y gastric bypass (RYGB), sleeve gastrectomy (SG), or adjustable gastric banding (AGB) as their primary procedure. We converted “hospital charges” to “cost,” using hospital specific cost-to-charge ratio. Inflation was adjusted using the annual consumer price index. Increased cost was defined as the top 20th percentile of the expenditure and its associated factors were analyzed using the logistic regression multivariate analysis.

**Results:** A total of 45,219 patients (20,966 RYGBs, 22,380 SGs, and 1,873 AGBs) were included. The median (interquartile range) calculated costs for RYGB, SG, and AGB were \$12,543 (\$9,970–\$15,857), \$10,531 (\$8,248–\$13,527), and \$9,219 (\$7,545–\$12,106), respectively ( $P < .001$ ). Robotic-assisted procedures had the highest impact on the cost (odds ratio 3.6, 95% confidence interval 3.2–4). Hospital cost of RYGB and SG increased linearly with the length of hospital stay and almost doubled after 7 days. Furthermore, multivariate analysis showed that certain co-morbidities and concurrent procedures were associated with an increased cost.

**Conclusion:** Factors contributing to the cost variation of bariatric procedures include co-morbidities, robotic platform, complexity of surgery, and hospital length of stay. (Surg Obes Relat Dis 2017;13:1284–1289.) © 2017 American Society for Metabolic and Bariatric Surgery. All rights reserved.

**Keywords:**

Bariatric surgery; Roux-en-Y gastric bypass; Sleeve gastrectomy; Cost analysis

\*Correspondence: Zhamak Khorgami, MD, Department of Surgery, University of Oklahoma, College of Medicine Tulsa, 1919 S. Wheeling Avenue, Suite 600, Tulsa, OK, USA 74104-5638.

E-mail: Zhamak-khorgami@ouhsc.edu

Bariatric surgery is currently the most effective treatment for morbid obesity. Numerous studies have shown the superiority of bariatric surgery over medical management for weight loss, improvement of obesity-related